

Swiss Hepatitis Symposium 2021

# Late presenters with viral hepatitis

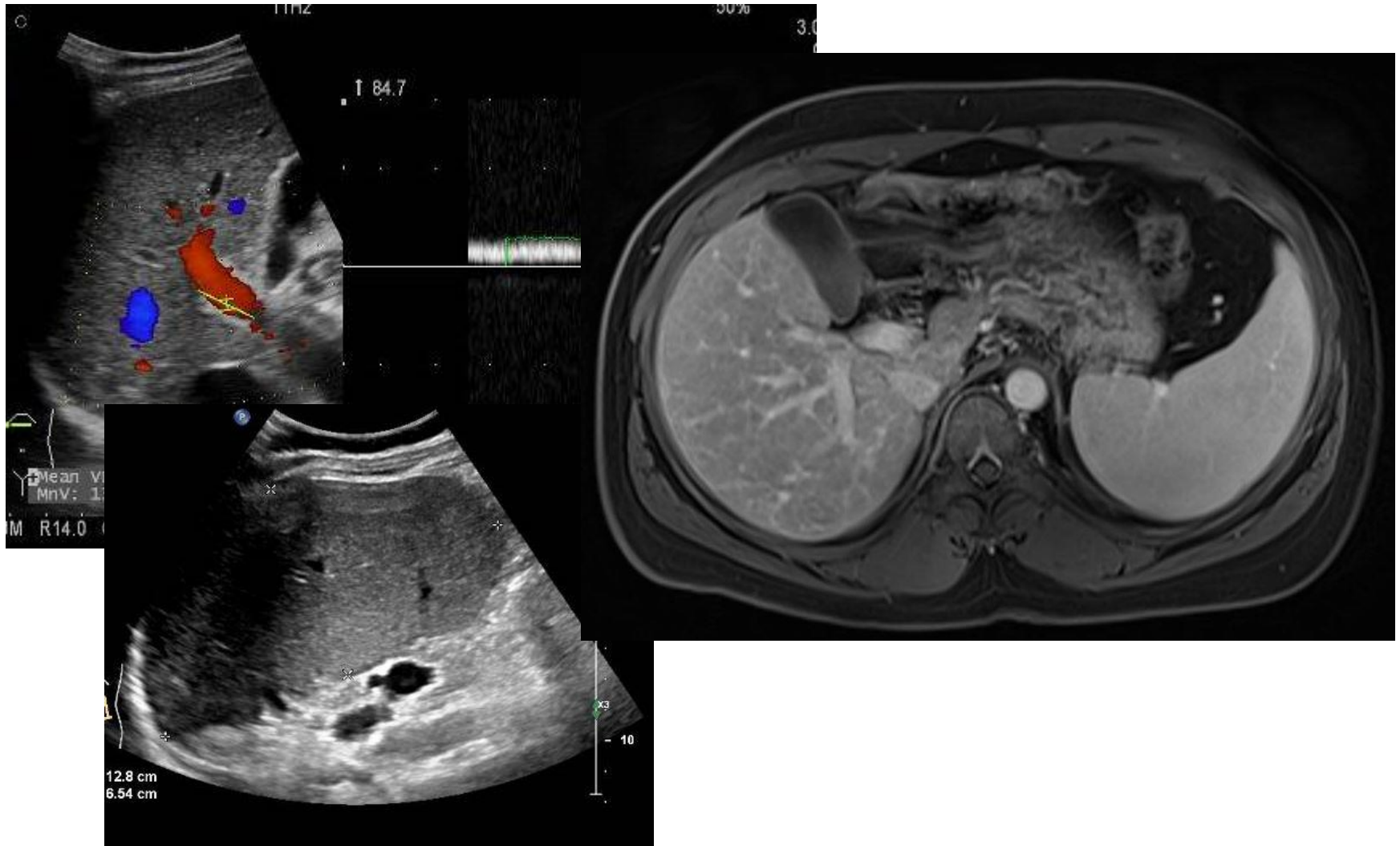Montserrat Fraga

Gastroenterology and Hepatology Service  
CHUV

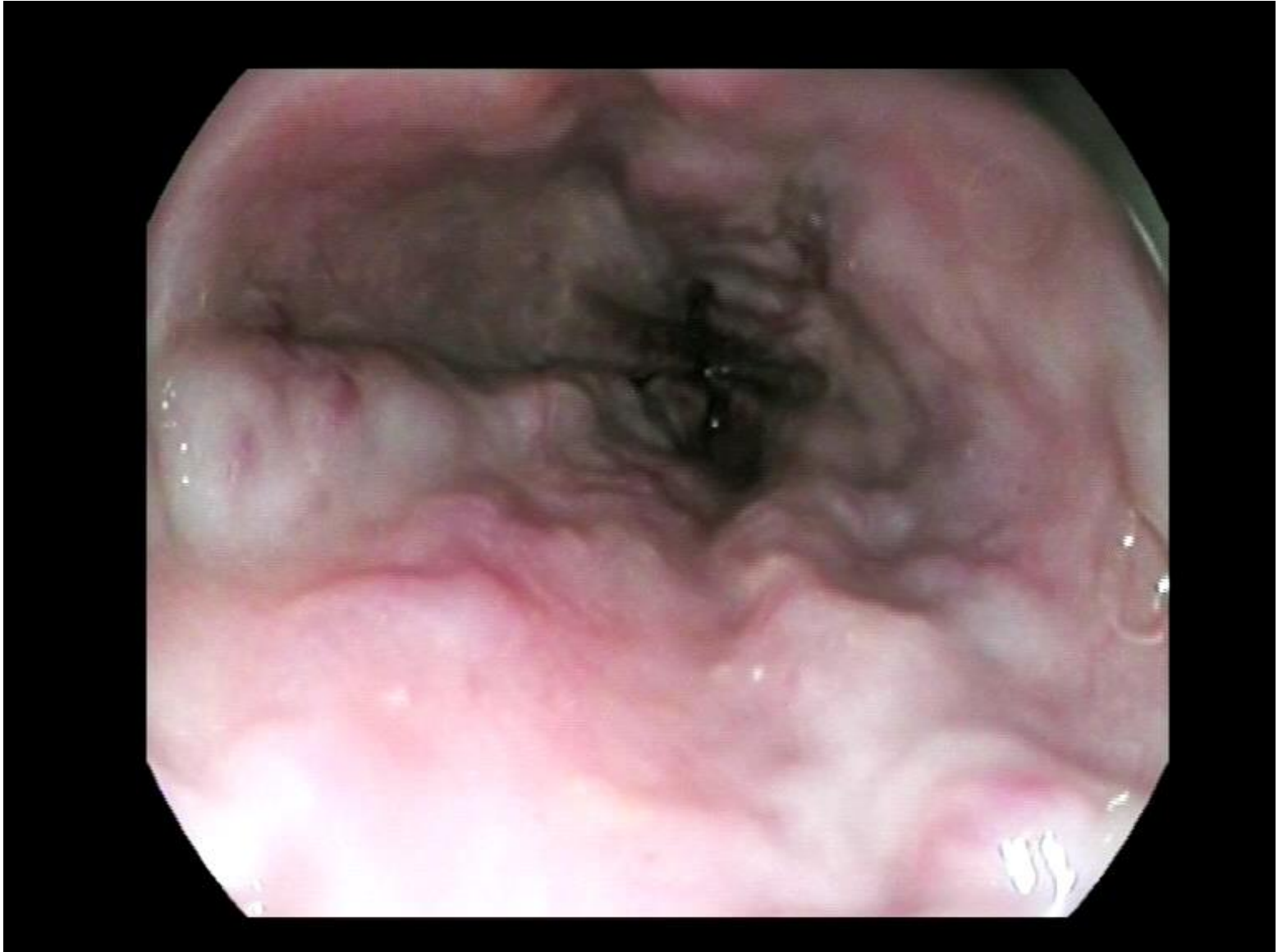
# Mr NS

- 24 yrs old, african origin, in CH since 2018
- Pregancy project
- ALT 111 U/l; AST 100 U/l
- Normal total bilirubin and albumin
- PT 60%, INR 1.3; Factor V 58%
- Platelets 76 G/l
  
- Anti-HCV -
- HBsAg +, HBeAg-, HBV DNA detected in very low concentrations
- Anti-HDV positive, HDV RNA 7.7 E+04

# US and MRI imaging



# Endoscopy



# Mrs NS

- CTP A cirrhosis
- Portal hypertension: Thombopenia and oesophageal varices
- No HCC: LIRADS-4 nodule under close monitoring

## Management

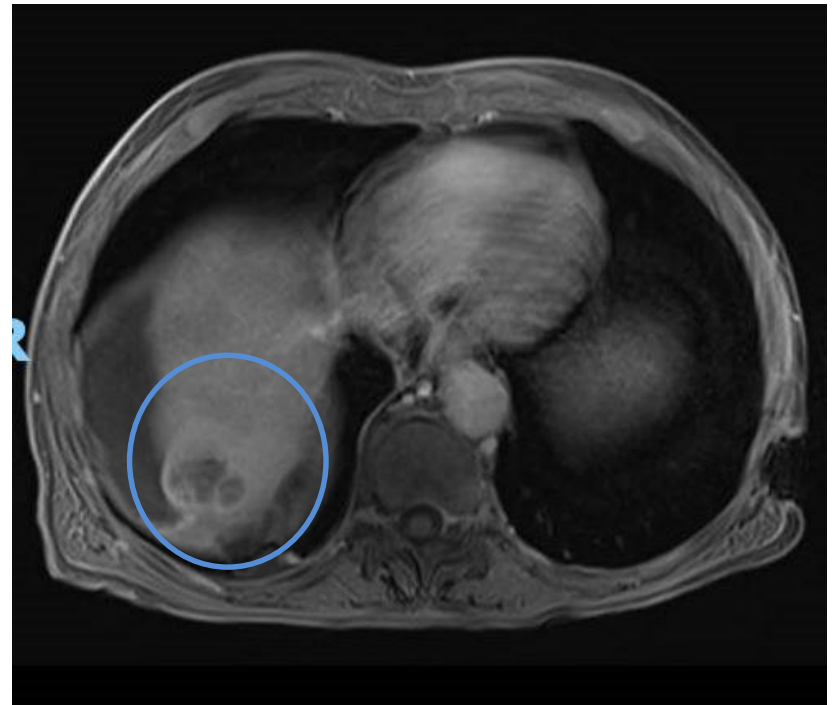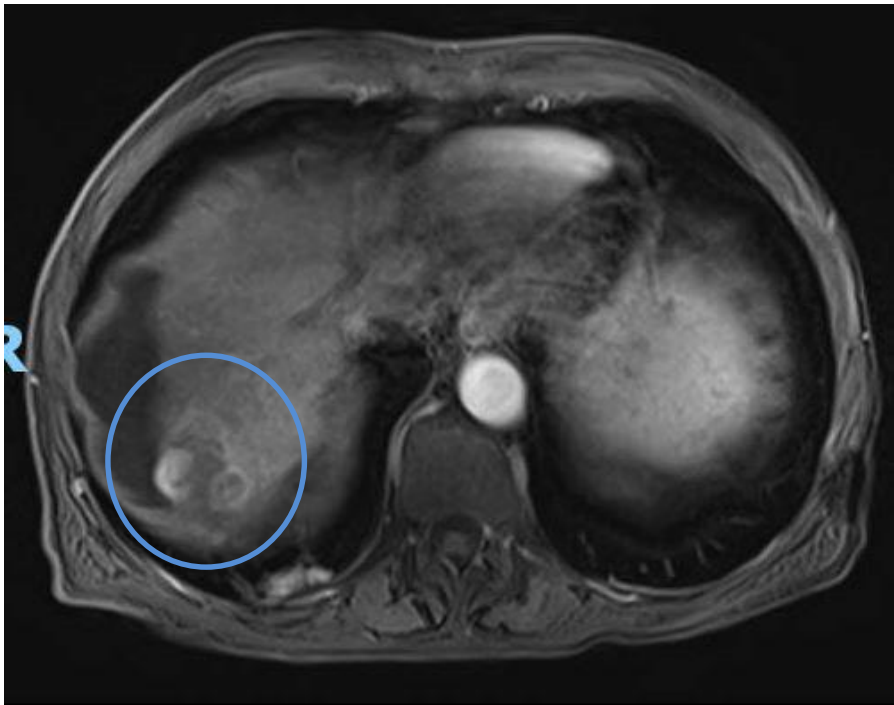
- OV band ligation
- HCC screening (MRI for LIRADS-4 nodule)
- TAF
- Ongoing bulevirtide compassionate request

# Mr EP

- Retired 66 yrs old male
- Chronic alcoholic consumption (2-3 units/day)
- Nov. 2021: Hospitalized with OA decompensation
  
- Clinic: florid ascitis and oedema
- Albumin 29 g/l, total bilirubin 22 umol/l, INR 1.7
- Platelets 70 G/l
- Preserved kidney function
- HCV PCR 5.0 E+04
- AFP 697 KUI/l

# Mr EP

CTP 8, MELD 15 points; portal hypertension and 4 cm HCC



# Mr EP

- Alcohol withdrawal
- Exclude extrahepatic disease
- HCV treatment (genotype pending)
- Treat ascitic decompensation
- HCV treatment (genotype pending)
- SIRT after liver recompensation?
- LT assesement (alcohol withdrawal)



# Many challenges ahead

- Improve patient's knowledge on viral hepatitis
- Improve linkage to care (migrants, IV drug consumers,.....)
- Improve awareness among primary care physicians
- Improve access to treatment and specialists in viral hepatitis management
- Delta: access to bulevirtide in CH?